

## SHORT COMMUNICATION

Tahir Turan · Ömer Levent Tuncay · Alp Usubütün  
Tarik Yonguç · Zafer Aybek · Özcan Atahan

## Renal tubular apoptosis after complete ureteral obstruction in the presence of hyperoxaluria

Received: 14 January 2000 / Accepted: 12 May 2000

**Abstract** Hyperoxaluria is a well-known cause of renal stone disease and in vitro studies have shown that oxalate crystals have a stimulatory effect on apoptosis of renal tubular epithelial cells. Total and partial ureteral obstruction also have an accelerating effect on apoptosis of renal tubular epithelial cells. The aim of the present study was to investigate the apoptotic effect of unilateral ureteral obstruction in the presence of hyperoxaluria on the rat kidney. Twenty-eight male Wistar rats were divided into four groups, with seven rats in each. The groups were named G1 (control), G2 (hyperoxaluric), G3 (obstructive) and G4 (hyperoxaluric + obstructive). G2 and G4 rats were given 1% ethylene glycol (a precursor for oxalates) in their drinking water. G1 and G2 rats underwent sham operation, while left proximal ureteral ligation with a 5-zero silk suture was performed on G3 and G4 animals. The rats were sacrificed 2 weeks after the operation; left nephrectomy was then performed. We searched for the apoptotic cells by direct immuno-peroxidase detection of digoxigenin-labeled genomic DNA. The mean  $\pm$  SD values of the apoptotic cell count was  $0.86 \pm 0.90$  in G1 and  $4.33 \pm 3.81$  in G2. The values for G3 and G4 were  $30.17 \pm 16.85$  and  $302.67 \pm 184.45$ , respectively. We found a statistically significant difference between all groups ( $P < 0.001$ ). When compared with the control group (G1), the mean apoptotic cell count was fivefold that of G2 and 35- and

351-fold those of G3 and G4, respectively. Our study demonstrated that hyperoxaluria with complete ureteral obstruction induces an excessive level of apoptosis, which is responsible for renal damage, and that ureteral obstruction is a more important factor for apoptosis than hyperoxaluria. Considering these data, we also believe that research studies for medical preventive measures must be considered for patients with ureteral obstruction and/or hyperoxaluria.

**Key words** Kidney · Ureter · Urinary obstruction · Hydronephrosis · Hyperoxaluria · Apoptosis

### Introduction

Apoptosis is an energy dependent, orderly, irreversible cellular process that leads to cell death and is distinct from necrosis. While cell death by necrosis is not a precisely controlled event, apoptosis can be precisely controlled on a cell by cell basis [4]. Apoptosis is now recognized as a critical biologic process not only in the physiology of normal cells, but in various disease states, both benign and malignant. Hyperoxaluria is a well-known cause of renal stone disease and tubulointerstitial (TI) damage. Increased urinary oxalate excretion can be detected in 0.3–50% of patients with calcium stones [7]. It was shown in vitro that calcium oxalate crystals induce apoptosis of renal tubular epithelial cells [9]. Studies with LLC-PK1 cells (a line of renal epithelial cells with characteristics of proximal tubular cells) also revealed that, when exposed to oxalate, these cells showed significant apoptotic changes, including condensation and margination of nuclear chromatin and DNA fragmentation [6]. Ethylene glycol is a well-known precursor of oxalate and produces hyperoxaluria and microliths when given to the rat as 0.8–1%/volume in drinking water [1, 8]. Total and partial ureteral obstruction also have an accelerating effect on apoptosis of renal tubular epithelial cells. The level of apoptosis

T. Turan · Ö. L. Tuncay · T. Yonguç  
Z. Aybek · Ö. Atahan  
Department of Urology, Pamukkale University,  
School of Medicine, Denizli, Turkey

Ö. L. Tuncay (✉)  
Pamukkale University, School of Medicine, Chairman,  
Department of Urology, PK: 66, 20100-Denizli, Turkey  
e-mail: omerl@tr-net.net.tr  
Tel.: +90-258-2655932 [+90-532-2722873];  
Fax: +90-258-2132874

A. Usubütün  
Department of Pathology, Hacettepe University,  
School of Medicine, Ankara, Turkey

observed in partial obstruction is approximately 65% of that recorded in the completely obstructed kidney [3, 5].

The aim of our study was to investigate the apoptotic effect of unilateral ureteral obstruction in the presence of hyperoxaluria on the rat kidney. To our knowledge, our investigation is the first report on apoptosis to include both hyperoxaluria and upper urinary tract obstruction.

## Materials and methods

Twenty-eight male Wistar rats, each weighing 200–300 g, were used and housed under standard conditions of heat and humidity on a 12-h light cycle with unlimited access to water and a standard diet. The animals were divided into four groups, with seven rats in each. The groups were named G1 (control), G2 (hyperoxaluric), G3 (obstructive) and G4 (hyperoxaluric + obstructive). Ethylene glycol, a well-known precursor for oxalates, was given to G2 and G4 rats in their drinking water as 1%/volume from the beginning of the study. Three days later, following intraperitoneal 0.04 mg/kg sodium pentobarbital anesthesia, a midline longitudinal abdominal incision was made. G1 and G2 animals underwent laparotomy (sham operation) only, while left proximal ureteral ligation with a 5-zero silk suture was performed on G3 and G4 animals. Animals were sacrificed 2 weeks later. At the time of sacrifice, urine was collected from the renal pelvis and/or the bladder; hyperoxaluria was confirmed by the presence of birefringent crystals in the urine. The presence of complete ureteral obstruction was demonstrated by the absence of antegrade methylene blue drainage from the renal pelvis to the bladder. Left nephrectomy was performed on all animals. All of the specimens were fixed in 10% neutral buffered formalin for 24 h and embedded in paraffin. We searched for the apoptotic cells by direct immuno-peroxidase detection of digoxigenin-labeled genomic DNA (ApopTag- Oncor Abbott Laboratories). We deparaffinized the sections, and applied proteinase K for 15 min and 3% hydrogen peroxidase for 5 min. We then applied equilibration buffer for 10 min and working strength enzyme (TDT: terminal deoxynucleotidyl transferase) at 37 °C for 1 h. Finally, working strength stop solution at 37 °C for 30 min was applied. Following treatment with digoxigenin-peroxidase for 30 min, sections were colored with diaminobenzidine and counterstained with methylgreen. Hematoxylin–eosin (HE) stained slides were then evaluated for the presence of necrosis. Necrosis was not detected on the HE slides, indicating that the stainings were positive for apoptosis. We counted the number of stainings under a 50 high power field (Hp), (Olympus BH2,  $\times 40$ ) for every case. The values were expressed as mean  $\pm$  SD. We used the Kruskal–Wallis and the Mann–Whitney *U*-test for the statistical analysis.

## Results

### Macroscopic examination

G1 (control) and G2 (hyperoxaluric) animals had normal renal capsule and the cortico-medullary junction was apparent. We did not observe any macroscopic pathologic features on renal tissue. In G3 (obstructive) and G4

(hyperoxaluric + obstructive) animals, the kidneys showed marked hydronephrotic changes. Some of them had only a small compressed parenchyma and showed features of multicystic lesion. The contralateral kidneys of G3 and G4 animals were slightly larger than those of the control group; the medulla was enlarged and pale.

### Apoptotic cell counting results

Table 1 summarizes the apoptotic cell counting results under 50 Hp. The mean  $\pm$  SD values of apoptotic cell count were  $0.86 \pm 0.90$  in G1 (control) and  $4.33 \pm 3.81$  in G2 (hyperoxaluric). The values for G3 (obstructive) and G4 (hyperoxaluric + obstructive) were  $30.17 \pm 16.85$  and  $302.67 \pm 184.45$ , respectively (Figs. 1, 2). We found a statistically significant difference between all of the groups ( $P < 0.001$ ). When compared with the control group (G1), the mean apoptotic cell count was fivefold that of G2 and 35- and 351-fold those of G3 and G4, respectively. The difference between each group was also obvious (Table 2).

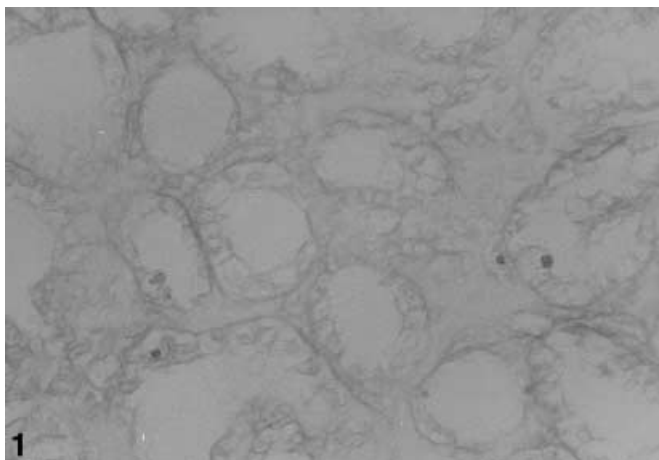
## Discussion

The morphological effects of complete ureteral obstruction on the rat kidney are well established. Hydronephrosis results in renal atrophy, primarily in the distal tubular epithelium, through the process of programmed cell death, i.e. apoptosis [3]. Alterations in the growth factor environment of the kidney, characterized by a decline in the constitutive expression of epidermal growth factor mRNA and an increase in the expression of transforming growth factor- $\beta$  mRNA, were also observed to occur with renal tubular apoptosis in both partial and total ureteral obstruction [5, 10].

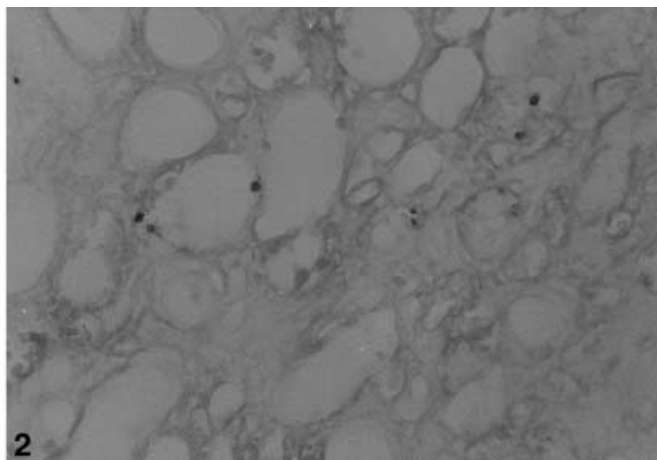
It is currently recognized that transforming growth factor- $\beta$  participates in the apoptotic process. It also modulates fibroblast–myofibroblast transformation and stimulates protein synthesis of types I, III and V collagen, fibronectin, and proteoglycans [2]. In the kidney, several cells express transforming growth factor- $\beta$ , such as mesangial cells, epithelial tubular cells, and fibroblasts. Recently, Toblli et al. [8] showed that hyperoxaluric rats had a marked deposition of transforming growth factor- $\beta$  in the interstitium. They also stated that enalapril (an ACE inhibitor) protects the kidney from the TI damage produced by oxalate by reducing angiotensin II production, transforming growth factor- $\beta$

**Table 1** Mean, standard deviation (SD), minimal and maximal (min–max), and median values of apoptotic cell counting according to the animal groups under 50 high power field (Hp)

Animal group	<i>n</i>	Mean	SD	Min–max	Median
Control (G1)	7	0.86	0.90	0–2	1.0
Hyperoxaluric (G2)	7	4.33	3.81	1–12	3.0
Obstructive (G3)	7	30.17	16.85	16–53	22.0
Obstructive + hyperoxaluric (G4)	7	302.67	184.45	104–546	253.0



**Fig. 1** Apoptotic bodies in renal tubules of rats with complete ureteral obstruction (immuno-staining  $\times 400$ )



**Fig. 2** Apoptotic bodies in renal tubules of rats with hyperoxaluria together with complete ureteral obstruction (immuno-staining  $\times 400$ )

**Table 2** Statistical significance of the mean values of apoptotic cell counting between the animal groups

Animal groups	<i>P</i> value
G1 vs G2	0.012
G1 vs G3	< 0.001
G1 vs G4	< 0.001
G2 vs G3	< 0.001
G2 vs G4	< 0.001
G3 vs G4	0.02

synthesis and deposition, collagen III interstitial deposition, and, thus, progressive TI fibrosis [8].

In our study, we showed that complete ureteral obstruction with hyperoxaluria (G4) produces a 351-fold increase in apoptosis in the ipsilateral kidney when compared with the controls. The increase in G4 was 70-fold when compared with hyperoxaluria only (G2) and was tenfold when compared with obstruction only (G3). When compared with the control group (G1), the mean apoptotic cell count was five that of G2 and 35-fold that of G3. In addition, there was a sevenfold increase in G3 when compared with G2. These findings show that ureteral obstruction is a more important factor for apoptosis than hyperoxaluria, and that complete ureteral obstruction with hyperoxaluria produces an excessive level of apoptosis, which results in renal parenchymal destruction. Because it is known that apoptosis occurs in rats during partial ureteral obstruction in a manner similar to that observed in complete ureteral obstruction, one can state that the same risk of apoptosis exists for partial ureteral obstruction with hyperoxaluria.

In conclusion, we showed that hyperoxaluria with complete ureteral obstruction induces an excessive level of apoptosis, which is responsible for renal damage, and

that ureteral obstruction is a more important factor for apoptosis than hyperoxaluria. In the future, research studies for medical preventive measures, such as the use of growth factors (or their inhibitors) as a drug and the use of enalapril, should be considered for patients with ureteral obstruction and/or hyperoxaluria.

## References

- Boeve ER, Ketelaars GAM, Vermeij M, Cao LC, Schröder FH, de Bruijn WC (1993) An ultrastructural study of experimentally induced microliths in rat proximal and distal tubules. *J Urol* 149: 893
- Bottinger EP, Letterio JJ, Roberts AB (1997) Biology of TGF- $\beta$  in knockout and transgenic mouse models. *Kidney Int* 51: 1355
- Gobe GC, Axelsen RA (1987) Genesis of renal tubular atrophy in experimental hydronephrosis in the rat. Role of apoptosis. *Lab Invest* 56: 273
- Gupta S (1996) Apoptosis/programmed cell death. A historical perspective. *Adv Exp Med Biol* 406: 1
- Kennedy WA, Stenberg A, Lackgren G, Hensle TW, Sawczuk IH (1994) Renal tubular apoptosis after partial ureteral obstruction. *J Urol* 152: 658
- Khan SR, Byer KJ, Thamilselvan S, Hackett RL, McCormack WT, Benson NA, Vaughn KL, Erdos CW (1999) Crystal-cell interaction and apoptosis in oxalate-associated injury of renal epithelial cells. *J Am Soc Nephrol* 14: 457
- Menon M, Mahle CJ (1983) Oxalate transport by intestinal brush border membrane vesicles. *West J Urol* 1: 163
- Toblli JE, Stella I, de Cavanagh E, Angerosa M, Inserra F, Ferder L (1999) Enalapril prevents tubulointerstitial lesions by hyperoxaluria. *Hypertension* 33: 225
- Tuncay OL, Gupta M, Singhal PC, Smith AD (1996) Renal tubular epithelial cells undergo apoptosis when exposed to uric acid and calcium oxalate monohydrate crystals. *J Urol* 155: 330A, abstract 1327
- Walton G, Buttyan R, Garcia-Montes E, Olsson CA, Hensle TW, Sawczuk IS (1992) Renal growth factor expression during the early phase of experimental hydronephrosis. *J Urol* 148: 510